



PATIENT

Koa Jacome

SPECIES

Canine

BREED

Mini Australian Shepherd

SEX

MN

AGE

7yr

WEIGHT

31lb

INTERPRETED BY

R. McKenzie Daniel,
 DVM, DABVP
 (Canine and Feline)

IMAGING PERFORMED BY

Sara Hansen

HOSPITAL NAME

Hello Vet for Pets

REFERRING VET

Dr Mullen

INVOICE
 24812

DATE

05/12/2026

PRESENTING CLINICAL SIGNS

ABNORMAL Labwork Values
 RBC 5.8 M/ul LOW 6.0 - 8.9
 Prev 6.7 2/2026
 Hematocrit (HCT) 42 % 41 - 61 (WNL)
 Prev 45 % 2/2026

ULTRASONOGRAPHIC EXAMINATION OF THE ABDOMEN

Urinary System

The urinary bladder, trigone, cystourethral junction, and visible pelvic urethra to a depth of 3 cm exhibited normal thickness and tone. Anechoic urine was present in the lumen with no evidence of urine/lumen sediment, mineral, or calculi. The ureteral papillae were normal. The ureters were not visible which is normal. No evidence of inflammatory or neoplastic changes was noted.

Normal size and margination were present in the kidneys. A normal 1:3 cortex / medulla ratio and normal corticomedullary definition were maintained. The echogenicity of the cortex was similar to or slightly less than normal liver parenchyma while the medulla echogenicity was hypoechoic to the cortex with no evidence of pelvic dilation. The left kidney measured 5.0 cm in length. The right kidney measured 4.8 cm in length.

The area of the aortic trifurcation was free of pathology.

No evidence of pathology in the area of the uterine remnant.

Adrenal Glands

The left adrenal gland was uniform in size and contour with a uniformly hypoechoic parenchyma. The left adrenal gland measured 0.57 cm width at the caudal pole. The right adrenal gland was uniform in size and contour with a uniformly hypoechoic parenchyma. The right adrenal gland measured 0.46 cm width at the caudal pole.

Spleen

The spleen exhibited a finely textured and homogenous parenchyma which was hyperechoic to the liver and renal cortical parenchyma. The capsule was smooth and regular without apparent expansion. The splenic vasculature at the hilus was normal in volume with no evidence of congestion or thrombosis. Acute to chronic inflammatory, neoplastic, or benign parenchyma changes were not noted.

Liver/Gallbladder

The liver was subjectively normal in size, structure, and contour. The liver parenchyma was uniform and hypoechoic to the spleen with a mild coarse echotexture. Normal vascular volume. The hepatic and portal vasculature were normal in appearance without signs of congestion. The gallbladder was non-distended in size with thin walls and primarily anechoic luminal content. The cystic and common bile ducts were normal.

Gastrointestinal

The stomach presented intact wall layering with a normal wall layer ratio. The lumen of the stomach was empty with no signs of ileus, obstruction or foreign material.



PATIENT

Koa Jacome

The small intestine presented intact wall layering with 1:3 muscularis/mucosa ratio. The lumen of the small intestine was empty with no signs of mechanical/metabolic ileus, obstruction or foreign material.

Normal visible colon wall layers were present with apparent formed feces in lumen.

SPECIES

Canine

Pancreas

The parenchyma of the left limb, body and right limb of the pancreas presented isoechoic to the adjacent omental fat. A normal curvilinear capsule contour of the pancreas was present. The visible pancreatic duct was normal. No signs of active inflammation or neoplastic disease was evident.

BREED

Mini Australian Shepherd

Free Abdomen

No omental masses, overt lymphadenopathy or peritoneal effusion was present.

SEX

MN

ULTRASONOGRAPHIC FINDINGS

Primary

- Sonographically unremarkable abdomen

AGE

7yr

INTERPRETATION OF THE FINDINGS & FURTHER RECOMMENDATIONS

No evidence of visceral pathology, including no evidence of neoplastic criteria. The definitive cause of the borderline decreased hematocrit was not obvious. Correlation with a CBC pathology review +/- infectious disease serology, if clinically indicated is recommended.

WEIGHT

31lb

INTERPRETED BY

R. McKenzie Daniel,
DVM, DABVP
(Canine and Feline)

IMAGING PERFORMED BY

Sara Hansen

HOSPITAL NAME

Hello Vet for Pets

REFERRING VET

Dr Mullen

INVOICE
24812

DATE

05/12/2026



PATIENT

Koa Jacome

SPECIES

Canine

BREED

Mini Australian Shepherd

SEX

MN

AGE

7yr

WEIGHT

31lb

INTERPRETED BY

R. McKenzie Daniel,
 DVM, DABVP
 (Canine and Feline)

IMAGING PERFORMED BY

Sara Hansen

HOSPITAL NAME

Hello Vet for Pets

REFERRING VET

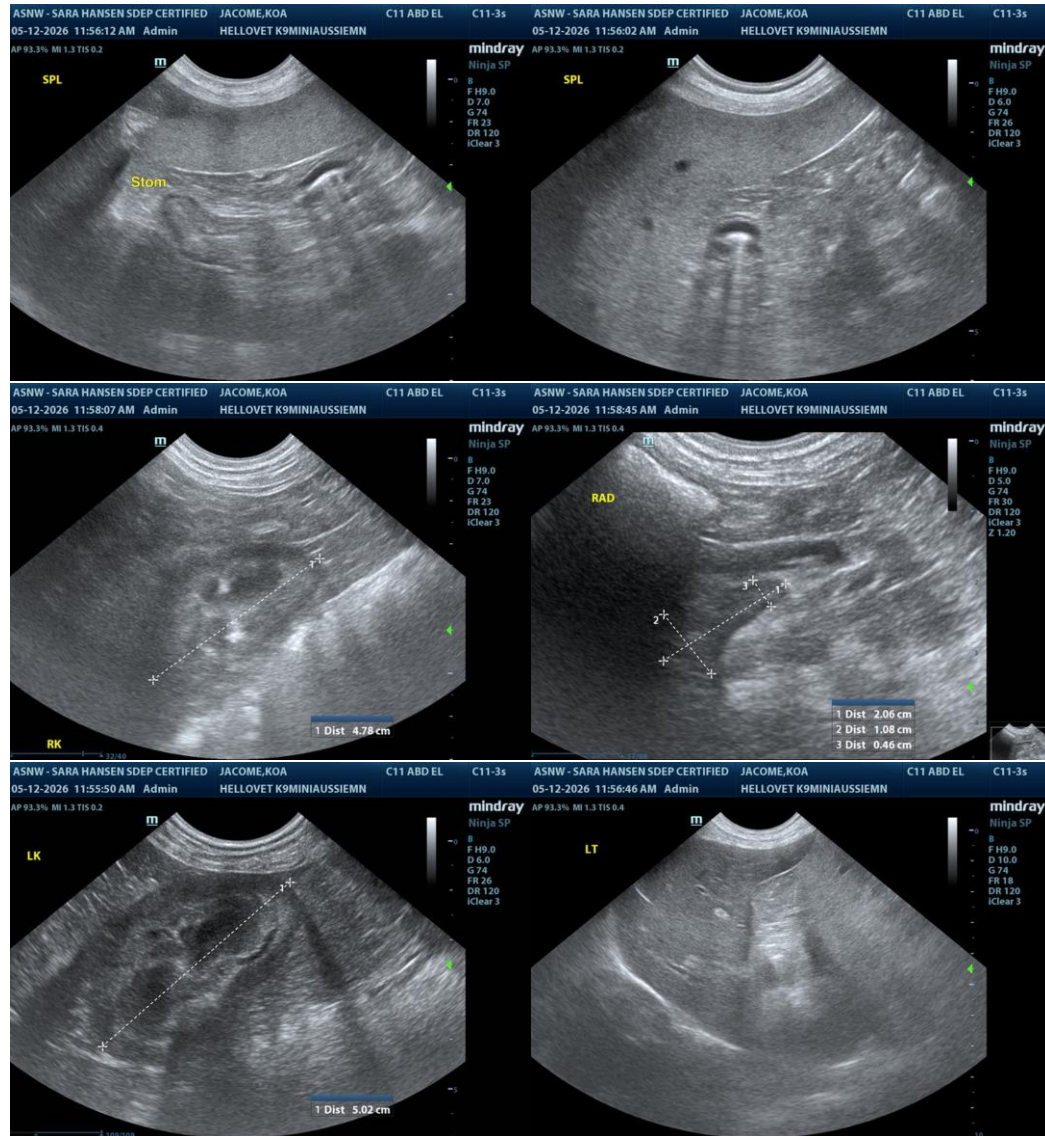
Dr Mullen

INVOICE

24812

DATE

05/12/2026





PATIENT

Koa Jacome

SPECIES

Canine

BREED

Mini Australian Shepherd

SEX

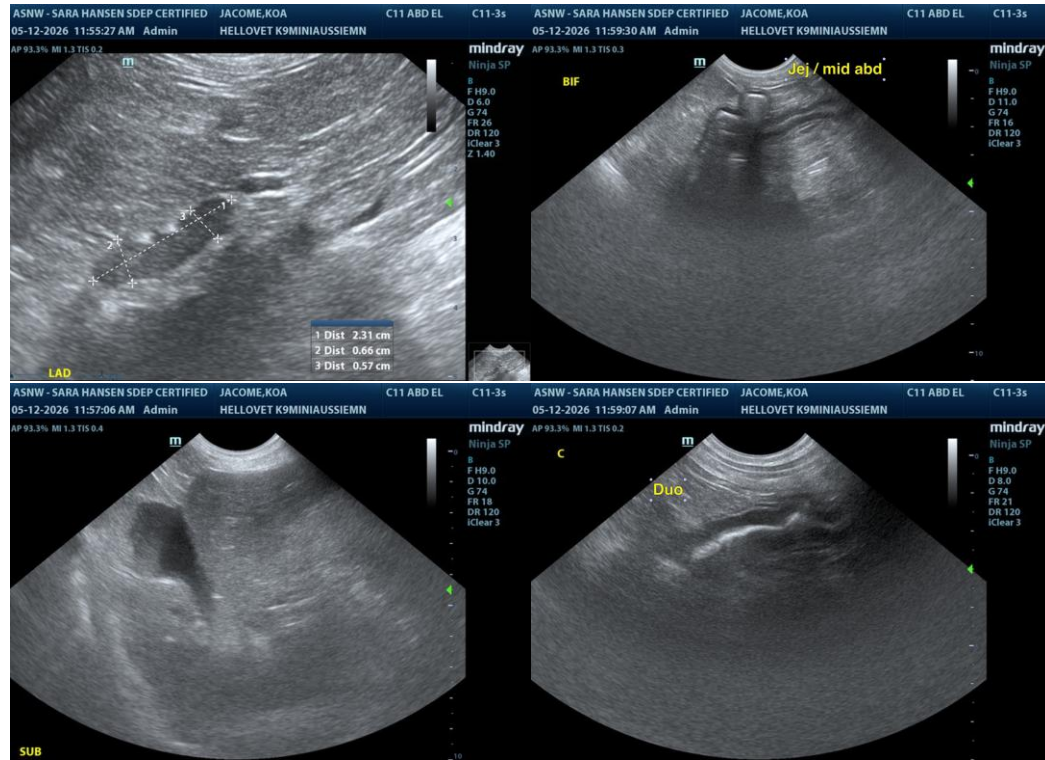
MN

AGE

7yr

WEIGHT

31lb



INTERPRETED BY

R. McKenzie Daniel,
 DVM, DABVP
 (Canine and Feline)

The information and recommendations provided are based on the images presented by the referring veterinarian/sonographer. No evaluation can be communicated regarding pathology that was not visible in the image/video clips provided.

Thank you for this referral. If the clinical or image interpretation does not parallel your findings or if I can be of any further assistance, please contact me.

IMAGING PERFORMED BY

Sara Hansen

R. McKenzie Daniel, DVM, DABVP (Canine/Feline Practice)
info@sonopath.com

HOSPITAL NAME

Hello Vet for Pets

REFERRING VET

Dr Mullen

INVOICE
 24812

DATE
 05/12/2026